

# Tetralogy of Fallot (TOF)

## With Hypoplastic Pulmonary Annulus

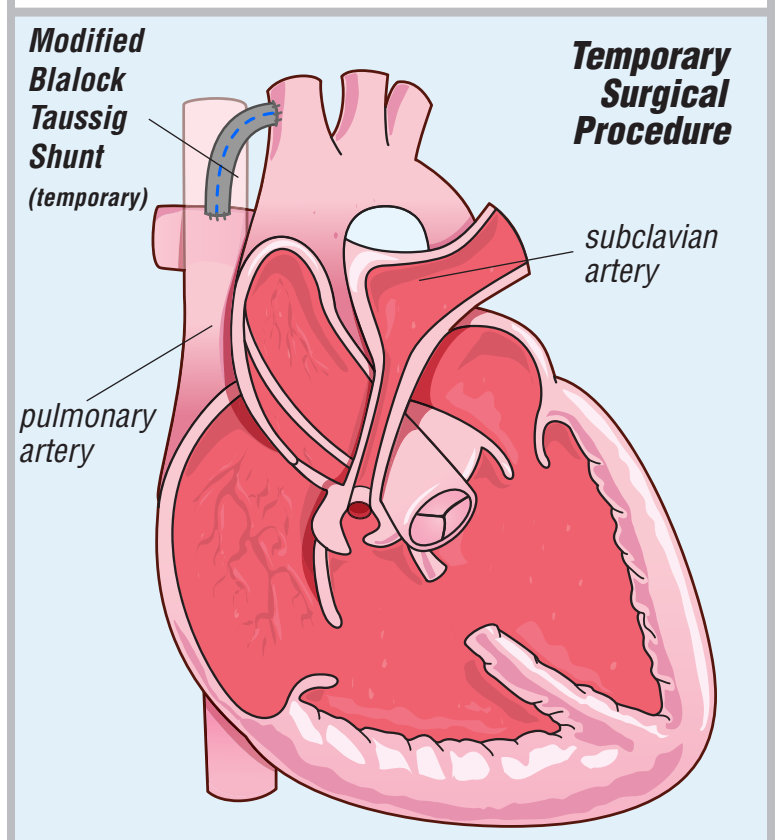
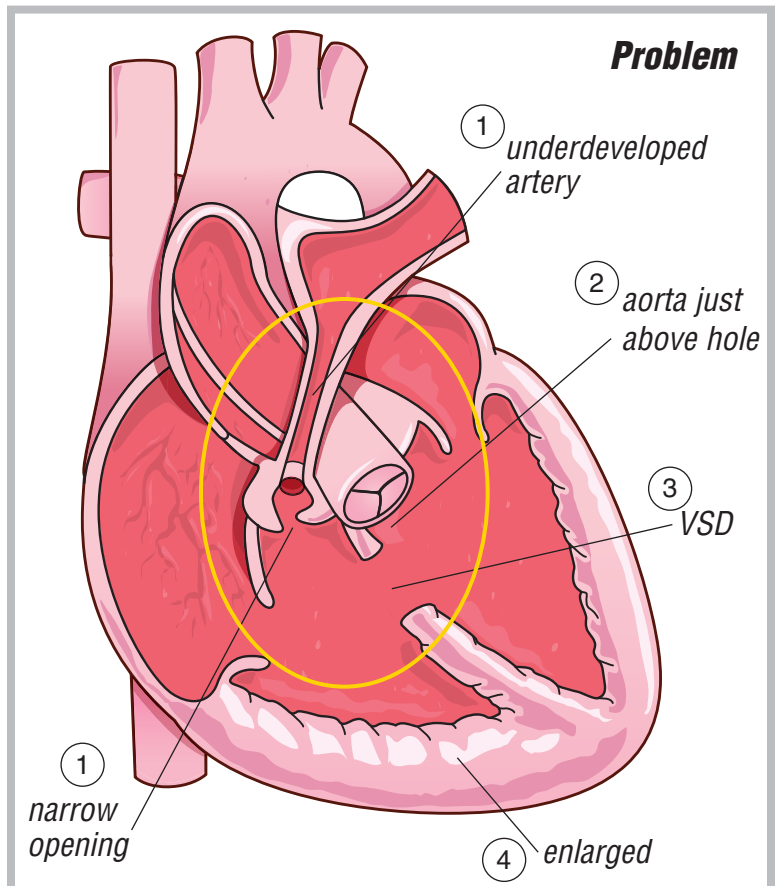
There are 4 heart problems:

1. a narrowing under or at the pulmonary valve (pulmonary stenosis). There is also underdeveloped (hypoplastic) pulmonary valve annulus (ring-shaped tissue of the pulmonary artery)
2. aorta is lined up just over the hole between the bottom 2 chambers
3. a hole between the bottom 2 chambers of the heart (ventricular septal defect)
4. an enlargement of the bottom right side of the heart

There is mixing of the red and blue blood through the hole between the bottom two chambers of the heart. Blood going to the lungs is restricted by the narrowing under the pulmonary valve. This protects the lungs from getting too much blood flow. The bottom right side of the heart becomes enlarged. This happens because it must hold too much blood and try to squeeze it through the narrowing to get to the lungs for oxygen.

Sometimes an infant is too sick or the pulmonary arteries are too small for the corrective surgery. In that case, a small tube (either from a blood vessel of the infant or artificial material) is placed from the subclavian artery into the pulmonary artery (Modified Blalock Taussig Shunt). The tube (shunt) allows blood to enter the lungs at all times. The shunt is removed at the time of the correction.

The shunt is placed through a thoracotomy (side) incision.



# ***Tetralogy of Fallot (TOF)***

## ***With Hypoplastic Pulmonary Annulus***

To correct the problem, the hole between the bottom chambers is closed. This is done using a patch of a synthetic material. Also, the narrowing under the pulmonary valve is relieved by cutting out the muscle blocking the blood flow to the pulmonary artery. This allows blood from the bottom right heart chamber to flow into the lungs as it should.

When the pulmonary valve annulus is underdeveloped, the correction involves relieving the narrowing. This is done with an incision across the pulmonary artery and pulmonary valve annulus and enlarging it with a wide football-shaped patch (transannular patch). This is patched using either a piece of the sac that the heart sits in (pericardium), human tissue (homograft) or synthetic material.

The surgery is done through a median sternotomy (chest) incision. If a shunt was placed earlier, it is also removed.

