

Pulmonary Atresia (PA)

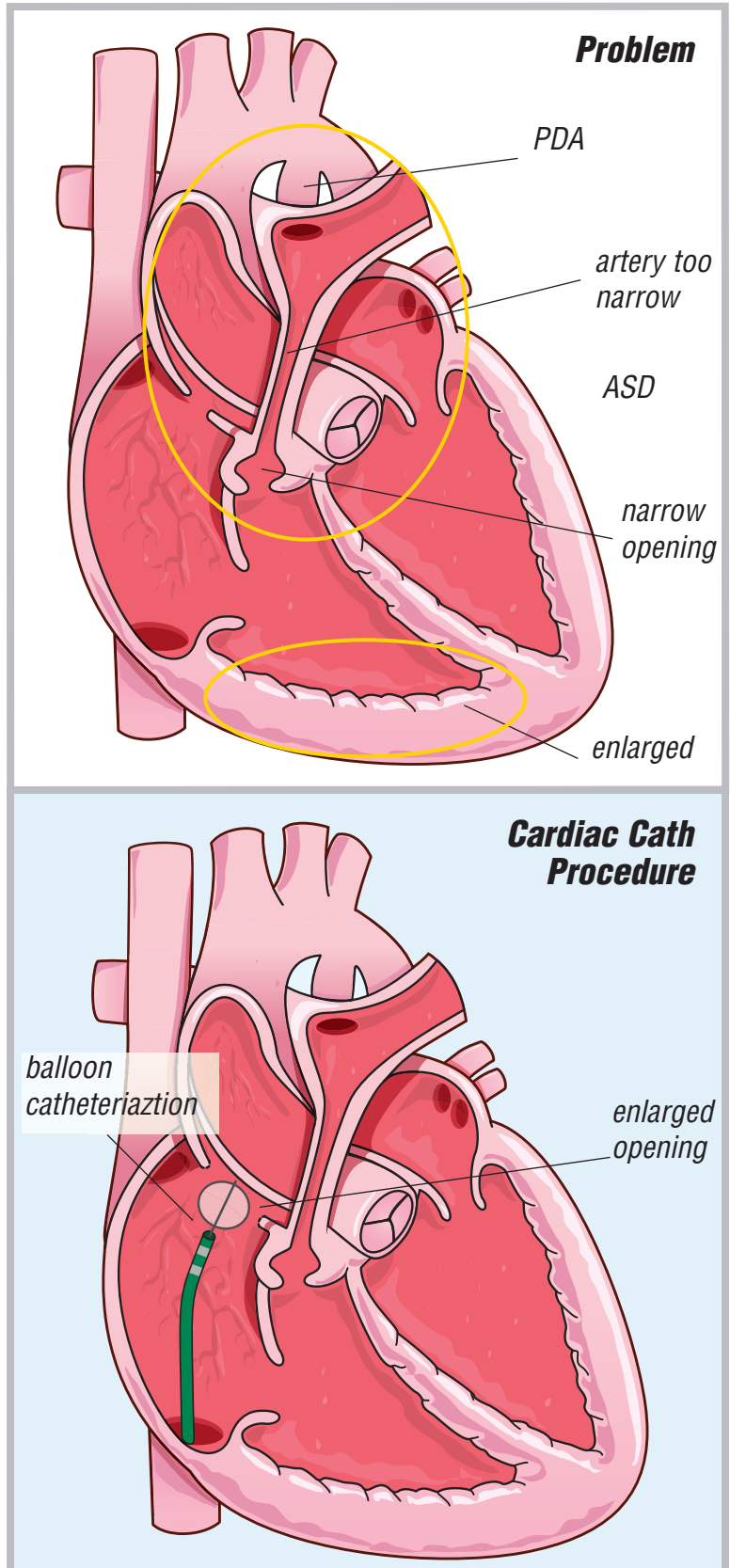
with Intact Ventricular Septum (2 ventricle approach)

PA occurs when:

- the pulmonary valve does not develop
- the main pulmonary artery is very small (The branch arteries from the main pulmonary artery may be small as well.)
- there is a narrowing beneath the pulmonary artery
- there is a hole between the top two chambers of the heart (atrial septal defect or ASD)
- there is a connecting blood vessel from the aorta to the pulmonary artery (patent ductus arteriosus or PDA)

When the main pulmonary artery and/or its branches are small, it is hard for blood to get to the lungs to pick up oxygen.

The ASD is enlarged to allow more mixing of the blood. This is done surgically or through a cardiac catheterization procedure called a balloon septostomy. A balloon is fed through a catheter into the right atrium, through the atrial septal defect and into the left atrium. It is then inflated and pulled back through the small opening to create a larger opening.



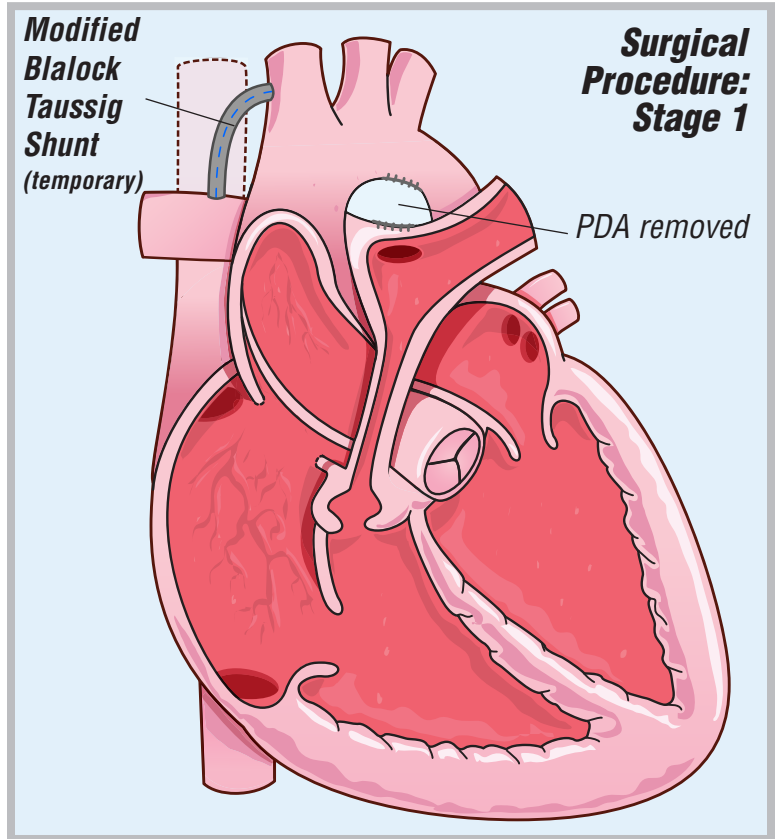
Pulmonary Atresia (PA)

with Intact Ventricular Septum (2 ventricle approach)

Stage 1

Stage 1 -

Most of the time, infants with PA have more than one operation. The first operation is most often the placement of a small tube (shunt) from the aorta or one of its branches to the pulmonary artery branch (Modified Blalock Taussig Shunt). The shunt is put in to give more blood to the lungs so the infant will have more oxygen-rich blood to the body. The shunt may be placed on the left, right or both sides of the pulmonary artery branch. The shunt(s) will be removed at the time of the corrective operation when no longer needed. The PDA is also removed. The shunt is done through a thoracotomy (side) incision.



Pulmonary Atresia (PA)

with Intact Ventricular Septum (2 ventricle approach) Stage 2 - Tube Repair

Stage 2- Tube Repair

The corrective surgery is aimed at directing the blood from the bottom right chamber of the heart to the branch arteries going to the lungs. The narrowing beneath the pulmonary valve is cut away. A tube is placed in the bottom right heart chamber and sewn into the branch pulmonary arteries. This tube is often a homograft (human tissue) vessel but can also be from man-made materials. The hole between the top two chambers of the heart is closed with a patch. This surgery is done through a median sternotomy (chest) incision.

Sometimes infants with pulmonary atresia and intact ventricular septum have an underdeveloped tricuspid valve and/or right ventricle, too. When this happens, additional surgery is needed to correct the problem.

