

Vascular Growth and Remodeling in Compensatory Lung Growth Following Right Lobectomy

Timothy D. Le Cras¹, Lucas G. Fernandez², Victor E. Laubach²

¹Division of Pulmonary Biology, Cincinnati Children's Hospital Medical Center & Department of Pediatrics, University of Cincinnati, Cincinnati, Ohio & ²Department of Surgery, University of Virginia Health System, Charlottesville, Virginia.

Introduction

- Compensatory lung growth following pneumonectomy (PNX) occurs in a variety of species & in humans, particularly children.
- Left PNX in rats increases growth of the right lung, with normal lung mass achieved two weeks after surgery.
- Removal of right lung lobes (right lobectomy: R-LBX) produces a similar response in left lung, with removal of the entire right lung resulting in a 2-fold increase in left lung mass.
- In rats and mice, following PNX there is complete restoration of normal total lung mass, volume, compliance, alveolar number, and normal cell populations.
- Takeda et al. (J. Appl. Physiol. 1999) measured hemodynamics in immature foxhounds following PNX. Measurements of cardiopulmonary function during exercise showed that mean pulmonary arterial pressure and resistance were elevated, while blood gases, cardiac output, & maximal oxygen uptake were normal.
- However, structural changes in the arterial system in response to PNX or LBX have not been reported.

Study Aims

- Determine whether compensatory lung growth following R-LBX causes:
- Vascular growth in proportion to growth of the remaining lung & amount of lung tissue removed;
 - Increased arterial branching;
 - Increased length of pulmonary arteries;
 - Changes in arterial density of alveolar regions;
 - Vascular remodeling & pulmonary hypertension

Methods

- Two (24% of lung mass; R-LBX2 group) or three right lobes (52% of lung mass; R-LBX3 group) were removed via thoracotomy from adult rats.
- Sham control animals underwent thoracotomy only.
- Lung weight & volume were measured three weeks after surgery
- Arteriograms were generated by barium perfusion & radiography (LeCras AJP Lung 2002).
- Area of the left lung arteriogram, arterial branching, & the length of arterial branches were measured & indexed to body weight (see Fig.1-3).
- To determine if R-LBX causes vascular remodeling & pulmonary hypertension, right ventricular hypertrophy & muscularization of arterioles were assessed.

Results

- Lung weight & volume index increased in R-LBX3 (2.3- & 1.8-fold respectively). R-LBX2 was not significant.
- Arterial area index of left lung increased 26% in R-LBX2 & 47% in R-LBX3 (Fig.4).
- Branching, size, & length of large arteries increased in R-LBX3, & to a lesser extent in R-LBX2 (Fig.4-5).
- Density of small pulmonary arteries were similar in R-LBX2 to sham controls, but 45% lower in R-LBX3 (Fig.6).
- Muscularization of arterioles increased in R-LBX3, but not R-LBX2 (Fig.7-8).
- Right ventricular hypertrophy increased 52% in R-LBX3, but not R-LBX2 (Fig.9).
- Blood flow (barium infusion) to infra-cardiac lobe was compromised (Fig.1) & this lobe appeared atrophied.

Fig 1. Arteriograms Following R-LBX

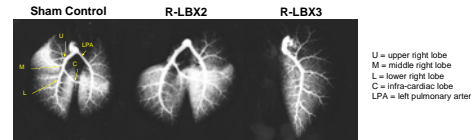

Fig 2. Left Lung Arteriograms

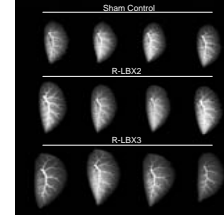


Fig 3. Arterial Measurements

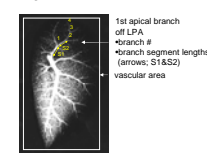


Fig 4. Increased Arterial Area & Branch Number following R-LBX

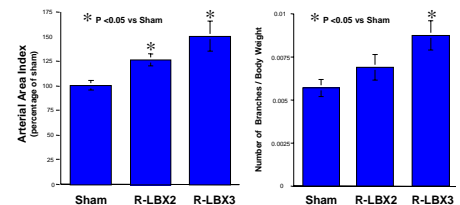


Fig 5. Increased Branch Length following R-LBX

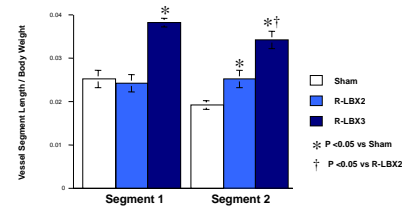


Fig 6. Distal Lung Histology & Arterial Density following R-LBX

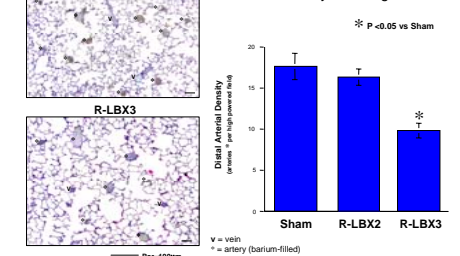


Fig 7. Smooth Muscle α -Actin in Left Lung of R-LBX3

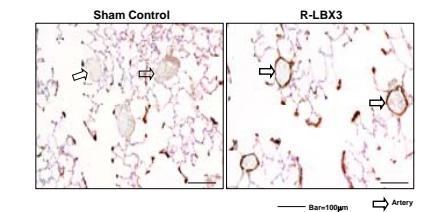


Fig 8. Increased Muscularization of Arterioles in R-LBX3

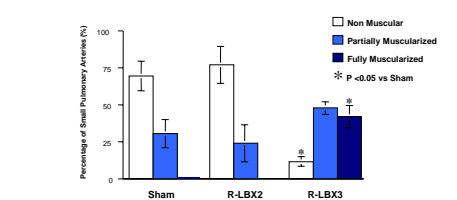
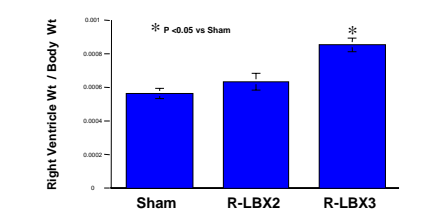


Fig 9. Increased Right Ventricular Hypertrophy in R-LBX3



Conclusions

- Right lobectomy induced arterial growth in the left lungs of adult rats, which was proportionate to the number of lobes removed.
- Pulmonary hypertension, vascular remodeling, & reduced arterial density were observed following removal of three right lobes, but not two.

Funding

- American Lung Association CI-31-N (TDLC) & Virginia Thoracic Society CI-52-N (VEL)
- NIH HL72894(TDLC)