
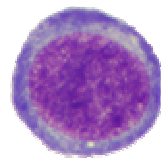
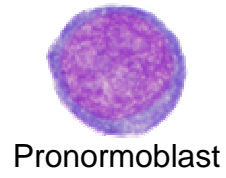


Erythropoiesis



Polychromatic normoblast



Orthochromatic normoblast



Reticulocyte



Red blood cell (erythrocyte)